Neuroscience Block Actual Final

MCQs:

1. A 30-year-old woman complains of unsteadiness while standing and walking. She tends to deviate to the left. Neurological examination reveals dysmetria on the left side, dysdiadokokinesia, and nystagmus that is more marked when she looks to the left side. Where is the lesion located?
   A. Right cerebellar hemisphere
   B. Left cerebellar hemisphere
   C. Left globus pallidus
   D. Left striatum
   E. Right substantia nigra

2. A 50-year-old hypertensive woman complains of numbness and weakness in her left leg and foot. Occlusion of which of the following vessels may account for this complaint?
   A. Anterior choroidal artery
   B. Internal carotid artery
   C. Anterior cerebral artery
   D. Middle cerebral artery
   E. Posterior cerebral artery

3. A 40-year-old dentist complains of headaches and inability to control his walking (gait). Neurological examination reveals loss of hearing on the right side and tinnitus, vertigo and nausea, wide based ataxic gait and lurching on the right side. Which one of the following is most likely involved in this case?
   A. Cerebellopontine angle
   B. Medial pons
   C. Lateral medulla
   D. Medial medulla
   E. Lateral pons

<u>Use the following scenario for the questions 4 and 5</u>

A 60-year-old patient with sudden onset of abnormal movements in his right limbs came to KFSHRC. He had increased appetite and hyperphagia and also developed mood and behavioral changes. Mental status and cranial nerves function was normal. In examination of motor system, no abnormality was detected in muscle tone; and force of extremities was normal. Deep tendon reflexes were symmetric and no pathologic reflexes were found. Involuntary movements, including continuous, arrhythmic and purposeless choreiform movements with occasional brisk proximal ballistic movements were seen affecting both upper and lower limbs on the right side with the same severity. The MRI showed an infarct in the sub-thalamic region.

4. He is suffering from which of the following conditions?
   A. Parkinson's disease
   B. Huntington's chorea
   C. Alzheimer's disease
   D. Hemiballismus
   E. Sydenham's chorea

5. The infarct in this case is due to occlusion of a branch of which one of the following arteries?
   A. Anterior cerebral
   B. Middle cerebral
   C. Posterior cerebral
   D. Anterior communicating
   E. Posterior communicating

6. A 20-year-old has an inherited progressive neuronal degeneration of brain. This results in twitching movements of head, grimacing movements in face, lips and tongue, gesticulating movements in distal parts of upper limbs and jerking movements in distal parts of lower limbs. The neurons in which one of the following parts of the brain were degenerated in this case?
   A. Globus pallidus externa
   B. Subthalamus
   C. Substantia nigra compacta
   D. Striatum
   E. Globus pallidus interna

7. Spina bifida results from failure of fusion of:
   A. Anterior neuropore
   B. Posterior neuropore
   C. Vertebral arches
   D. Vertebral bodies
   E. Neural tube

8. During development of medulla, the general visceral efferent column differentiates into which of the following nuclei?
   A. Ambigus
   B. Dorsal vagal
   C. Hypoglossal
   D. Cochlear
   E. Solitarius

9. If the skull fails to develop, meninges and neural tissue may protrude over the head. This condition is known as:
   A. Meningocele
   B. Meningomyelocele
   C. Meningoencephalocele
   D. Meningohydroencephalocele
   E. Meningocystocele

10. The CT scan below shows an area of infarct. Occlusion of which one of the following arteries can lead to this finding?
    A. Anterior cerebral
    B. Middle cerebral
    C. Posterior cerebral
    D. Superior cerebellar
    E. Posterior choroidal

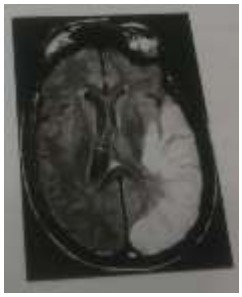

11. Stimulation of the frontal oculomotor area (area 8) would most likely produce:
    A. Contraction of the muscles of the contralateral legs
    B. Visual agnosia
    C. Auditory hallucinations
    D. Conjugate eye movements
    E. Fasciculations in the muscles of the ipsilateral hands

12. Which of the following connects Wernicke's area in the temporal lobe to Broca's area in the frontal lobe?
    A. Inferior longitudinal fasciculus
    B. Uncinate fasciculus
    C. Arcuate fasciculus
    D. Corona radiata
    E. Cingulum

13. An impairment in the ability to perform certain types of learned, complex movements (referred to as apraxia) usually results from a lesion of which of the following?
    A. Precentral gyrus
    B. Postcentral gyrus
    C. Premotor cortex
    D. Prefrontal cortex
    E. Primary motor cortex

14. The vascular structure found around the attachment of the falx cerebri with the tentorium cerebelli is the:
    A. Sigmoid sinus
    B. Superior sagittal sinus
    C. Inferior petrosal sinus
    D. Transverse sinus
    E. Straight sinus

15. A 67-year-old woman suffered a cerebral infarction 3 weeks ago. She frequently forgets to put her left arm into the sleeve of her blouse, always leaves food on the left side of her plate, and frequently bumps into things on her left side. She has no language disorder or paralysis of speech. Which of the following represents the most likely site of cerebral cortical damage in this patient?
    A. Motor cortex in the right hemisphere
    B. Posterior parietal cortex in the right hemisphere
    C. Posterior parietal cortex in the left hemisphere
    D. Inferior temporal cortex in the right hemisphere
    E. Inferior temporal cortex in the left hemisphere

Use the following clinical scenario for questions 16-18

Mrs. Khan, a 64-year-old lady, with a history of diabetes, hypertension, peripheral vascular disease and coronary artery disease presented to the ER with vomiting, vertigo and gait unsteadiness. She also started having hoarseness of voice and was brought to the ER soon after. On examination, her vitals were: pulse 95/min, BP 220/100, temp= 37. Her initial neurological examination showed left sided Horner's Syndrome and loss of pain and temperature sensation on the left side of the face and the right side of the body. Weakness of palate, pharynx and vocal cords was noted on the left, along with left sided cerebellar ataxia.

16. Which if the following tracts in involved in Horner's syndrome?
    A. Corticospinal
    B. Spinocerebellar
    C. Hypothalamospinal
    D. Spinothalamic
    E. Tectospinal

17. Left sided cerebellar ataxia was noted due to damage to which of the following?
    A. Left cerebellum
    B. Left cochlear nucleus
    C. Left inferior cerebellar peduncle
    D. Left principal sensory nucleus
    E. Left spinal trigeminal tract and nucleus

18. Left sided weakness of palate, pharynx and vocal cords was noted because of damage to which of the following?
    A. Nucleus ambiguus
    B. Nucleus cuneatus
    C. Nucleus dorsalis
    D. Nucleus gracilis
    E. Nucleus solitarius

19. Which of the following cranial nerve nuclei is responsible for the salivary secretion from the parotid gland?
    A. Edinger-Westphal nucleus
    B. Inferior colliculus
    C. Superior colliculus
    D. Inferior salivatory nucleus
    E. Superior salivatory nucleus

20. What is the most sensitive sign on non-contrast CT for detecting early hydrocephalus?
    A. Cortical sulcal effacement
    B. Uncal herniation
    C. Enlarged third ventricle
    D. Enlarged fourth ventricle
    E. Enlarged temporal horns of lateral ventricles

21. A 70-year-old diabetic presents with slurred speech and right sided weakness, which spontaneously resolved over 1-2 hours. Initial unenhanced CT is normal. Further investigation by MRI is requested. What sequence is most sensitive for diagnosing acute ischemia in the brain?
    A. T2 W1
    B. T1 W1 post-Gadolinium
    C. Diffusion weighted imaging
    D. FLAIR
    E. Proton density

22. A 70-year-old male with a low score on the Glasgow coma scale is admitted to a medical assessment unit. MRI shows a large area in the left MCA distribution returning high signal on diffusion-weighted images and low signal in the corresponding area on the ADC map. The most likely diagnosis is:
    A. Acute hypertensive bleed
    B. Acute cerebral infarction
    C. Old cerebral infarction
    D. Sagittal sinus thrombosis
    E. 14-day old cerebral infarction

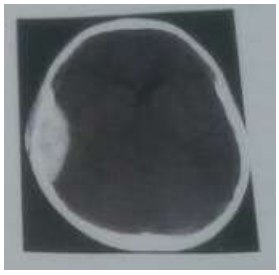

23. A 30-year-old man with a history of medically refractory partial seizures undergoes MRI examination as work up for epilepsy. Coronal T2 W1 shows left hippocampal atrophy with prominent temporal horn of the lateral ventricle (white arrow in image). Which condition is most likely to result in such a pattern of volume loss?
    A. Pick's disease
    B. Encephalitis
    C. Parkinson's disease
    D. Medial temporal sclerosis
    E. Temporal lobe infarction

24. A 28-year-old unconscious man was admitted to the Accident & emergency department after a motorcycle accident. He briefly regained consciousness and then became comatose. CT of the head shows a fracture of the right petrosal bone with mild midline shift. Which of the following best describes the hemorrhage?
    A. Acute subarachnoid
    B. Acute subdural
    C. Acute extradural
    D. Acute intracerebral

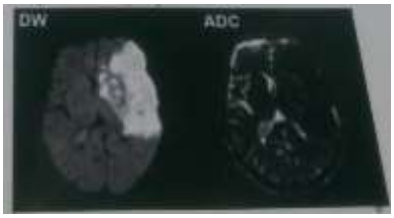

25. A 35-year-old woman with spastic paraparesis presents with an episode of right facial paralysis. A FLAIR axial image of the brain and a contrast enhanced T1 image of the cervical spine and shown below. What is the most likely diagnosis?
    A. Multifocal hemorrhage
    B. Vasculitis
    C. Multiple sclerosis
    D. Transverse myelitis
    E. Small vessel ischemic disease

26. Increased neural activity before the onset of a skilled voluntary movement is first seen in which of the following?
    A. Midbrain
    B. Cerebellum
    C. Precentral motor cortex
    D. Spinal alpha motor neurons
    E. Cortical unimodal association areas

27. Which of the following cortical functions is the most lateralized in humans?
    A. Vision
    B. Hearing
    C. Writing
    D. Language
    E. Handedness

28. The axons of which of the following cortical cells project to cerebellar nuclei in order to influence outflow?
    A. Golgi
    B. Basket
    C. Stellate
    D. Purkinje
    E. Granular

29. Patients with Parkinson's disease may obtain symptomatic relief from which of the following?
    A. Increasing dopamine levels in the striatum
    B. Increasing acetylcholine levels in the striatum
    C. Increasing GABAergic stimulation of GPe
    D. Increasing the tonic drive from GPi to motor thalamus
    E. Blocking glutamatergic input from the cortex to the striatum

<u>Use the following clinical scenario for questions 30-32</u>

A 21-year-old man has been using a banned substance containing a contaminant toxin that is known to selectively destroy groups of neurons in the brainstem. He presented with tremors and rigidity.

30. Which of the following neuronal groups in the brainstem might be related, either directly or indirectly, to this person's condition?
    A. Vestibular nuclei
    B. Substantia nigra
    C. Trigeminal spinal nuclei
    D. Dorsal column nuclei
    E. Raphe nuclei

31. The neurotransmitter loss most likely linked to the symptoms is?
    A. Acetylcholine
    B. Dopamine
    C. Glycine
    D. Norepinephrine
    E. Serotonin

32. A common approach toward the treatment of this disorder would be to administer:
    A. A serotonin reuptake inhibitor
    B. A CNS depressant
    C. A dopaminergic agonist
    D. A noradrenergic antagonist
    E. An NMDA blocker

33. Which of the following would you expect to observe as a result of bilateral loss of hippocampal function?
    A. Disappearance of sematic memory
    B. Loss of working memory
    C. Loss of the ability to encode events of the recent past in long term memory
    D. Loss of the ability to recall faces and forms but not the ability to recall printed or spoken words
    E. Production of inappropriate emotional responses when recalling events of the recent past

34. You are examining a 40-year-old male with recent complaints of poor memory. He is presented with a string of randomly ordered numbers which he is then asked to repeat. Which of the following types of memory are you testing?
    A. Immediate
    B. Working
    C. Implicit
    D. Semantic
    E. Episodic

35. You are examining a 42-year-old woman with recent complaints of poor memory. She is asked to itemize what she did before going to bed last night. Which of the following types of memory are you testing?
    A. Immediate
    B. Working
    C. Implicit
    D. Semantic
    E. Episodic

36. Encoding of new memory in the hippocampus requires long term potentiation of synaptic functions. Which of the following neurotransmitters is essential in the initiation of this process?
    A. Nitric oxide
    B. Glutamate
    C. Acetylcholine
    D. Dopamine
    E. Norepinephrine

37. During periods of relaxed wakefulness with closed eyes, a normal individual's ECG will display a predominance of which of the following ECG rhythms?
    A. Spike and wave rhythm
    B. A wave
    C. B wave
    D. Δ wave
    E. Θ wave

38. Electroencephalographic waves maybe recorded from the brain when electrodes are placed on the scalp. Which of the following is the primary source of the recorded electoral activity?
    A. Synaptic potentials from cortical pyramidal cell dendrites
    B. Action potentials from cortical pyramidal cells
    C. Synaptic potentials in cerebellar cortex
    D. Action potentials from deep nuclei of cerebral cortex
    E. Electrical activity in thalamic sensory nuclei activated by the ascending reticular activating system

39. Which of the following EEG rhythms, if recorded from an awake young adult, will be indicative of serious brain damage?
    A. Alpha rhythm
    B. Beta rhythm
    C. Theta rhythm
    D. Delta rhythm
    E. Gamma rhythm

40. Which of the following stages of sleep is associated with the most synchronized EEG pattern?
    A. Stage 1
    B. Stage 2
    C. Stage 3
    D. Stage 4
    E. REM

41. A patient is confused and displays localized jerks in his right hand, which progress to jerks of entire arm with a brief loss of consciousness. This disorder can best be characterized as a:
    A. Generalized seizure
    B. Absence seizure
    C. Tonic seizure
    D. Simple partial seizure
    E. Complex partial seizure

42. Which of the following is a feature of cardio-embolic stroke?
    A. Usually sudden in onset
    B. Lasts for less than 24 hours
    C. Leaves no residual deficit
    D. Usually subcortical (white matter) involvement
    E. Is not hemorrhagic

43. Which of the following is a risk factor for venous sinus thrombosis?
    A. Infection
    B. Dehydration
    C. Hypercoagulable state
    D. Male gender
    E. Vasculitis

44. In decerebrate posturing:
    A. Elbows and the knees are extended
    B. Elbows are flexed and the knees are extended
    C. Elbows are extended and the knees are flexed
    D. Elbows and the knees are flexed
    E. Elbows and the knees are in neutral position

45. Which of the following hemorrhages has a lens (concave) shape on a brain CT scan?
    A. Intracerebral
    B. Subdural
    C. Epidural
    D. Subarachnoid
    E. Intrathecal

46. If a patient withdraws from painful stimuli, his motor response in Glasgow Coma Scale will be:
    A. 1
    B. 2
    C. 3
    D. 4
    E. 5

47. A 54-year-old man with 3 months history of headaches in brought to the emergency department following a generalized tonic-clonic seizure. On physical examination, he has weakness on the right side. An MRI of his brain shows a large, irregular, 6cm mass in the left cerebral hemisphere that extends across the corpus callosum. A stereotaxic biopsy of the mass is done and histological findings are shown in the figure. Which of the following neoplasms is he most likely to have?
    A. Meningioma
    B. Medulloblastoma
    C. Hemangioblastoma
    D. Glioblastoma multiforme
    E. Diffuse large B-cell lymphoma

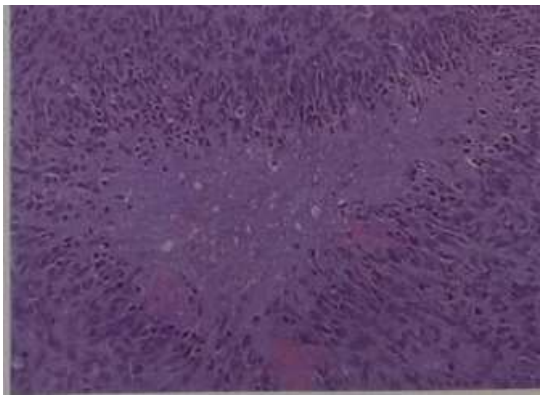

48. A 65-year-old woman who fell to the ground and hit her head, is taken to the emergency department. Physical examination is unremarkable. CT scan of the head shows no hemorrhage or fracture, but there is a 5cm mass beneath dura that compresses the underlying right parietal lobe. The mass is surgically removed. Histologic sections from the mass would most likely reveal:
    A. Antoni A areas and Antoni B areas with Verocay bodies
    B. Whorls of meningoepithelial cells and scattered psammoma bodies
    C. Endothelial proliferation and nuclear pseudo palisading around necrotic area
    D. Fried-egg appearance of tumor cells with scattered calcification
    E. Sheets of anaplastic small blue cells with Homer-Wright rosettes

49. A 48-year-old man presented to ENT department with history of tinnitus and diminished hearing for the past 6 months. On physical examination, he has decreased hearing on both sides. A head MRI shows bilateral sharply circumscribed, 2-3 cm masses in cerebellopontine angle. Family screening reveals a similarly affected 32-year-old sibling. An inherited mutation involving which of the following genes is most likely to be present in this patient?
    A. NF2
    B. EGFR
    C. FAP
    D. TSC1
    E. VHL

50. A 72-year-old alcoholic woman had problems in remembering things for past one year. Her immediate family members noticed that she confabulates quite often. She dies as consequence of hepatic failure. At autopsy, morphological changes are seen in mammillary bodies and medial dorsal nucleus of the thalamus. Which of the following is the most likely diagnosis in this case?
    A. Pick disease
    B. Multiple system atrophy
    C. Central pontine myelinolysis
    D. Wernicke-Korsakoff syndrome
    E. Metachromatic leukodystrophy

51. A 30-year-old woman is brought to the hospital after an episode of weakness. On examination, she has decreased strength in her left upper extremity and decreased light touch sensation over her right lower extremity. She has no decrease in mentation. A lumber puncture is performed, and the CSF contains elevated levels of IgG and oligoclonal bands on gel electrophoresis. Which of the following pathologic findings in CNS is she most likely to have?
    A. Gliosis with atrophy of caudate and putamen
    B. Loss of pigmented neurons in the substancia nigra
    C. Perivascular lymphocytes with demyelinated axons in white matter
    D. Increased neurofibrillary tangles and neuritic plaques in the neocortex
    E. Foci of multinucleated cells and macrophages in grey and white matter

52. A 46-year-old man stuck his head against the wind shield of his van in a road-side accident. He lost consciousness at the time or at any point thereafter. Physical examination showed minor ?! in his forehead. However, 6 weeks later, he begins complaining of headaches and becoming irritable. Which of the following intracranial vascular abnormalities most likely developed in this man?
    A. Epidural hematoma
    B. Subdural hematoma
    C. Intracerebral hematoma
    D. Subarachnoid hemorrhage
    E. Intraventricular hemorrhage

53. A 68-year-old man is undergoing hip joint replacement for long standing osteoarthritis. During this procedure, his systolic blood pressure drops to 50 mm Hg that persists for 20 min despite intervention with pressor agents. Which of the following pathological lesions is most likely to occur in his brain as a consequence of this prolonged hypotensive episode?
    A. Diffuse axonal injury
    B. Linear parasagittal infarction
    C. Lacunar infarcts of basal ganglia
    D. Parietal lobe hemorrhagic infarction
    E. Duret hemorrhage in midbrain and upper pons

54. A 58-year-old man was brought to the hospital after suddenly losing consciousness. His son told attending physician that his father is hypertensive but he is not taking his medication regularly. In hospital when he is aroused, ha cannot speak and he cannot move his left leg. Which of the following intracranial pathologic abnormalities is most likely to be present?
    A. Subarachnoid hemorrhage
    B. Basal ganglia hemorrhage
    C. Cerebral venous thrombosis
    D. Rupture of middle meningeal artery
    E. Embolic occlusion of middle cerebral artery

55. Patients with insulin resistance syndrome are more likely to develop Alzheimer's disease than the general population because of which one of the following reasons?
    A. Increased aggregation of Aβ peptide
    B. Decreased clearance of Aβ peptide
    C. Presence of extra copy of the APP gene
    D. Mutation of presenilin-I
    E. Mutation in APP

56. Cognitive decline seen in Alzheimer's disease correlates better with the number of:
    A. Diffuse plaques
    B. Senile plaques
    C. Neuritic plaques
    D. Neurofibrillary tangles
    E. CAG repeats in APP gene

57. The pallor of substancia nigra seen in Parkinson's disease involves loss of which of the following?
    A. Melanin
    B. Catecholamine
    C. Dopamine
    D. Serotonin
    E. Huntingtin

58. Mutations of which of the following protein-coding genes may result in the development of the autosomal-dominant form of Parkinson disease?
    A. α-synuclein
    B. Huntingtin
    C. APP
    D. BDNF
    E. Tau

59. Lewy bodies are mainly composed of:
    A. Neurofibrillary tangles
    B. Diffuse amyloid plaques
    C. Dystrophin
    D. α-synuclein
    E. GABA

60. Which of the following is the most likely pathogen in meningitis in patients older than 50 years of age?
    A. Streptococcal pneumoniae
    B. N.meningitidis
    C. E. coli
    D. H. influenza
    E. Listeria monocytogenes

61. Which of the following is the cornerstone in the diagnosis of bacterial meningitis?
    A. CSF fluid analysis
    B. Blood culture
    C. CT scan
    D. MRI
    E. Pharyngeal swab

62. Mr. John has suffered from a stroke in the area shown in the figure. He occasionally disregards the left side of the body. Which one of the following cognitive test was advised after reviewing the patient's neuroradiological report?
    A. Wisconsin's Sorting Task
    B. Go-No-Go Task
    C. False-Belief Task
    D. Cross the line task
    E. Word association task

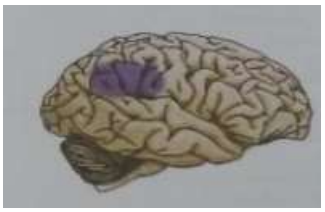

63. After the nasty accident, the family of Mr. James noticed that he was making poor decisions. Which of the following cortical regions was most likely affected?
    A. Insular cortex
    B. Arcuate fasciculus
    C. Right inferior temporal gyrus
    D. Right parietal cortex
    E. Prefrontal cortex

64. Subcortical meningioma has left a patient unable to respond appropriately to spoken communication even though speech was well understood. The lesion is most likely present at:
    A. Broca's area
    B. Wernicke's area
    C. Arcuate fasciculus
    D. Angular gyrus
    E. Exner's area

65. A tumor is expanding in the left inferior frontal lobe. Which cognitive deficits would be associated with the lesion?
    A. Expressive aphasia
    B. Receptive aphasia
    C. Agraphia and receptive aphasia
    D. Agraphia and expressive aphasia
    E. Alexia

66. Which cognitive deficit would the patient exhibit with a lesion shown in the Figure of the right hemisphere?
    A. Inability to recognize faces
    B. Inhibition of inappropriate behavioral tendencies
    C. Expressive aphasia
    D. Receptive aphasia
    E. Emotional coloring of speech

67. A patient resuscitated form cardiac arrest for more than a few minutes had no recollection of the events that preceded the cardiac arrest and was unable to recall events some hours after being resuscitated. Which structure of the brain was affected?
    A. Dorsolateral prefrontal cortex
    B. Orbitofrontal cortex
    C. Hippocampus
    D. Amygdala
    E. Basal ganglia

68. After a car accident Mr. John could not remember the immediate events that preceded his accident. What would the most likely diagnosis be?
    A. Concussion
    B. Retrograde amnesia
    C. Anterograde amnesia
    D. Transient global amnesia
    E. Huntington's disease

69. "In which country are the pyramids? ". This question is an example of which memory system?
    A. Episodic
    B. Working
    C. Immediate
    D. Semantic
    E. Procedural

70. Which memory type is affected in Huntington's and Parkinson's disease?
    A. Short-term
    B. Long-term
    C. Declarative
    D. Non-declarative
    E. Episodic

71. Which region of the brain would encode the information depicted in the image?
    A. Putamen
    B. Hippocampus
    C. Amygdala
    D. Insula
    E. Cingulate cortex

72. A 44-year-old male, who was admitted for selective surgery 3 days before, had developed symptoms of increased agitation, tachycardia, irritability and anger. The most likely diagnosis is:
    A. Alcohol withdrawal
    B. Diabetes
    C. Seizure disorder
    D. Major depression
    E. Hospital phobia

73. The following mechanism leads to addiction:
    A. Increase serotonin in nucleus accumbens
    B. Increase norepinephrine in frontal lobe
    C. Increase dopamine in nucleus accumbens
    D. Increase the firing of locus coeruleus neurons
    E. Increase serotonin in the ventral tegmental area

74. Emotional memory (aversive learning) is mainly stored in:
    A. Orbitofrontal cortex
    B. Pons
    C. Amygdala
    D. Dorsolateral prefrontal cortex
    E. Anterior cingulate cortex

75. Norepinephrine in secreted in the brain from:
    A. Locus coeruleus
    B. Prefrontal cortex
    C. Dorsal raphe nucleus
    D. Ventral tegmental area
    E. Amygdala

76. The following symptom distinguishes depression from anxiety:
    A. Early morning waking
    B. Low self-esteem
    C. Difficulty falling asleep
    D. Decrease interest (anhedonia)
    E. Suicidal thoughts

77. A 35-year-old lady developed depressive symptoms after hearing that she is suffering from cancer. The symptoms lasted only for a few days and subsided gradually over one week. She most likely had:
    A. Depression
    B. Normal reaction
    C. Depression secondary to cancer
    D. Acute stress disorder
    E. Postpartum depression

78. Which of the following is most likely a risk factor to develop depression?
    A. Smoking marijuana once a month
    B. Diagnosed to have eczema and takes steroids
    C. Perfectionistic personality and depressed parents
    D. Recently got pregnant and happily married
    E. Having normal dizygotic twins

79. A 23-year-old engineering school student has a father with bipolar mood disorder. He now presents with his first depressive episode without any past history of a manic episode. He is best treated with:
    A. Fluoxetine
    B. Lithium
    C. Carbamazepine
    D. Lorazepam
    E. Paracetamol

80. A 22-year-old woman presenting with irritable mood, grandiosity, pressured speech, distractibility, decreased need for sleep and excessive involvement in high risk behavior. These symptoms occurring for the first time. The most likely diagnosis is:
    A. Major depression
    B. Bipolar mood disorder
    C. Schizophrenia
    D. Obsessive compulsive disorder
    E. Attention deficit hyperactivity disorder (ADHD)

81. Last night, the media broadcasted a 55-year-old man who committed suicide by gunshot. He most likely has this history:
    A. Early dementia
    B. Social alcohol drinking
    C. narcissistic personality disorder
    D. Schizophrenia stable on medication
    E. Chronic depression with hopelessness

82. Delirium is a medical emergency that requires immediate management and attention. Which of the following patient scenarios has the highest risk of developing delirium:
    A. 25-year-old man with 5 years history of social alcohol drinking
    B. 66-year-old man with well-controlled hypertension
    C. 81-year-old lady with lung infection
    D. 35-year-old pregnant lady, having labour contractions
    E. 77-year-old depressed man with normal cognition

83. A 60-year-old man presented with fluctuating cognitive function, visual hallucinations, Parkinsonian features and recurrent delirium. This patient most likely has:
    A. Alzheimer's dementia
    B. Vascular dementia
    C. Lewy body dementia
    D. Delirium
    E. Depression

84. 55-year-old man was taking antidepressants but with poor response, presented with impaired concentration and attention, sadness and suicidal thoughts. Lab workup showed normal results except vitamin D deficiency. The most likely diagnosis:
    A. Dementia
    B. Depression
    C. Delirium
    D. Anxiety disorder
    E. Drug-induced cognitive disorder

85. A 77-year-old man has difficulty performing motor tasks like wearing clothes. When instructed to do so, he understands the command but fails to perform the task. This symptom is called:
    A. Aphasia
    B. Amnesia
    C. Agnosia
    D. Apraxia
    E. Anomia

86. A 45-year-old single scientist at a university who is academically functioning well, is medically healthy, works many hours, has no friends and not interested to have sex. His first-degree relatives are most likely to develop:
    A. Depression
    B. Anxiety disorder
    C. Schizophrenia
    D. Substance abuse
    E. Bipolar mood disorder

87. A 25-year-old single lady who presented with self-harm and suicidal behavior, had unstable relationships, chronic feelings of emptiness and a disturbed identity. She was also impulsive and angry. This personality disordered patient would most benefit from:
    A. Antidepressants
    B. Mood stabilizers
    C. Antipsychotics
    D. Psychotherapy
    E. Social skills training

88. A 45-year-old male surgeon is highly functioning at work. His family and co-workers complain that he is arrogant, feeling "full of himself", envious and exploit others for his selfish needs. This man most likely has:
    A. Narcissistic personality disorder
    B. Histrionic personality disorder
    C. Paranoid personality disorder
    D. Paranoid schizophrenia
    E. Grandiose delusions

89. A 33-year-old lawyer is highly functioning in his law office. He is meticulous for detail, underestimates pleasure time, works during holidays and devotes life to his career. He is a perfectionistic. This lawyer has:
    A. Schizoid personality disorder
    B. Obsessive compulsive personality disorder
    C. Obsessive compulsive disorder
    D. Antisocial personality disorder
    E. Normal personality

90. A 21-year-old female college student who experiences frequent migraine headaches was asking for help. Her headaches were not relieved with other counter analgesics. The neurologist advises that she should start which drug from the following at the first site of pain?
    A. Sumatriptan
    B. Paracetamol
    C. Propranolol
    D. Topiramate
    E. Verapamil

91. Which of the following is a contraindication for Triptans use?
    A. Peptic ulcer disease
    B. Diabetes mellitus
    C. Hypothyroidism
    D. Coronary artery disease
    E. Dyslipidemia

92. A 22-year-old male was invited to a rave party. He was tired after a ling travel but wanted to attend the party anyway. Which one of the following drugs may help him in energizing, allowing him to attend the all-night long party?
    A. Cocaine
    B. Khat
    C. LSD
    D. MDMA
    E. Marijuana

93. A 31-year-old university graduate could not find a suitable job after repeated interviews. In some desperate moment, he embarked on a drug of abuse. Soon after taking the drug, he experienced extreme anxiety, dysphoria and became terrorized. The situation became so intolerable that he attempted suicide. Which one of the following drugs might he have taken?
    A. Cocaine
    B. LSD
    C. MDMA
    D. Synthetic cathinone
    E. Methamphetamine

94. Which of the following is the major mechanism underlying currently available antiepileptic drugs?
    A. Releasing dopamine pools
    B. Blocking sodium or calcium ion channels
    C. Blocking GABA neurotransmission
    D. Activating glutamate neurotransmission
    E. Inhibiting dopamine synthesis

95. Which of the following are the main side-effects of first-generation antipsychotics?
    A. Acute dyskinesia explained by dopaminergic blocking effect
    B. Acute dyskinesia explained by glutamatergic blocking effect
    C. Tardive dyskinesia explained by serotonin blocking effect
    D. Hypoprolactinemia explained by an adrenergic blocking effect
    E. Anxiety explained by the histaminergic blocking effect

96. Which of the following mechanisms applies to second-generation antipsychotics?
    A. A higher 5-HT_{2a} receptor occupancy than the first-generation antipsychotics
    B. A higher D2 receptor occupancy explaining more dopaminergic side effects
    C. Other serotonin receptor occupancies (5-HT_{1a}, 5-HT_6, 5-HT_7) contributing to a severe weight loss
    D. H1 and/or α1 receptor antagonisms explaining frequent motor effects
    E. Dopamine transporter inhibition explaining antidepressant effects

97. Which of the following drugs is used in Parkinson's disease treatment?
    A. Dopamine, as the endogenous neurotransmitter
    B. Pramipexole, as a dopamine receptor agonist
    C. Amphetamine, as a dopamine releaser
    D. Methylphenidate, as a dopamine transporter inhibitor
    E. Memantine, as a glutamate receptor inhibitor

98. Which one of the following is one of the mechanisms underlying Alzheimer's drug treatment?
    A. Inhibition of acetylcholinesterase
    B. Activation of acetylcholinesterase
    C. Antagonism of muscarinic cholinergic receptors
    D. Glutamate transporter inhibitor
    E. Agonism of glutamate NMDA receptors

99. Which of the following is true for memantine?
    A. It is an irreversible glutamate receptor antagonist
    B. It is a reversible glutamate receptor antagonist
    C. It improves cognitive functions in the majority of patients
    D. It is classically used in patient with mild cognitive impairments
    E. Its more frequent side effects involve the GIT

100. A 3-year-old child died of encephalitis. MRI and autopsy pictures are provided. The NAAT on the tissue and CSF detected DNA virus. Select the most appropriate statement related to this clinical scenario.
    A. Control of the vectors is the major public health measure to prevent additional cases
    B. A vaccine should have been useful in preventing the infection
    C. Acyclovir should have been administered
    D. The CSF would show increased proteins and decreased glucose
    E. Rifampicin should be administered for prophylaxis to all close contacts

SAQ:

1. A middle-aged woman appeared in the clinic because of difficulties in walking and a sagging of the corner of the mouth. Her history showed that these abnormalities were the latest in the long series of events. Recently, she experienced intermittent painful sensations in the right side of face, and now it has become numb. Within past several weeks, she noticed a tendency to sway to the right while walking. These recent events have been accompanied by difficulty in swallowing and hoarseness.
   5 years back, the woman had a series of dizzy spells and complained of tinnitus in the right ear. Somewhat later, she found it difficult to close her eyes tightly, and the corner of the mouth on the right side began to droop and did not rise when she smiled.
   Neurologic examination revealed a loss of taste in the right side of the tongue. No corneal reflex can be elicited on right side.

   A. Locate the site of the lesion and give one justification (2 marks)
   B. Name the structures involved in causing following abnormalities seen in this case (10 marks)
   C. Define ataxia and tinnitus (4 marks)
   D. What is corneal reflex? Why it was lost in this case? (4 marks)

2. A 37-year-old man developed involuntary twitching movements in his left thumb. Within 30s, he notices that the twitching has spread to his entire left hand and that involuntary movements have developed in his left forearm and the left side of the face. He cannot recall what happened subsequently, but his wife reports that he fell down and the entire left side of his body appeared to be twitching. He appeared to be unresponsive for about 3 min and confused for another 15 min. During the episode, he bit his tongue and wet his pants. There is no history of head trauma or recent illness.

   A. Which part of the motor cortex did this patient's seizure start? Be as specify as you can (2 marks)
   B. How would you categorize/classify this type of seizure activity? (2 marks)
   C. What electroencephalographic wave patterns would you expect to find in this patient during the seizure? (2 marks)
   D. If this is this patient's first episode, list 3 investigations that might be relevant (3 marks)

Investigation	Rationale

   E. 2 months and 3 similar seizure episodes later, the patient was diagnosed with epilepsy. Name TWO first-line drugs that could be used for treatment. (2 marks)
   F. For the 2 drugs you named above, give 2 adverse effects for each drug (4 marks)

Exam questions were collected by Exam Committee members and other external contributors.
This document was compiled, edited and revised by Mariam Hendaz. Don't forget us in your Prayers.
We may have done some mistakes, so always refer back to the lectures in case of any doubt.
Contact me at mhendaz@alfaisal.edu for any concern. ***Best of Luck!***